

Repeated Behavior of Deliberate Foreign Body Ingestion in a Patient with Psychiatric Disorder: A Case Report

Francisco Javier Buils^{1,2*} , Guillermo Renau¹, Juan José Sánchez Cano^{1,2}, Manuel Rodríguez^{1,2}, Javier Menéndez¹, Nico Lobo¹, Stephanie Haupt¹, Miriam Galiana¹, Lidia Sevillano¹, Antonio Sánchez^{1,2}

¹Department of General and Digestive Surgery, Sant Joan University Hospital, Reus, Tarragona, Spain.

²Rovira I Virgili University, Faculty of Medicine and Health Sciences, Surgery Unit, Tarragona, Spain.

Correspondence to: Francisco Javier Buils, Department of General and Digestive Surgery, Sant Joan University Hospital, Reus, Tarragona, Spain.

Received date: July 25, 2024; **Accepted date:** August 13, 2024; **Published date:** August 20, 2024

Citation: Buils FJ, Renau G, Sánchez Cano JJ, et al. Repeated Behavior of Deliberate Foreign Body Ingestion in a Patient with Psychiatric Disorder: A Case Report. *J Med Res Surg.* 2024;5(4):95-97. doi: 10.52916/jmrs244144

Copyright: ©2024 Buils FJ, et al. This is an open-access article distributed under the terms of the Creative Commons Attribution License, which permits unrestricted use, distribution and reproduction in any medium, provided the original author and source are credited.

ABSTRACT

Self-destructive behavior within the psychiatric sphere can occur both directly and indirectly. Intentional ingestion of foreign bodies has rarely been discussed in the psychiatric literature. Most reports of foreign body ingestion have been in prisoners. Psychiatric patients who swallow sharp foreign objects have serious psychopathologies, possible suicidal ideation, and past psychiatric hospitalizations.

We believe that the approach to this group of patients should be focused on the one hand, on the resolution of the surgical pathology aimed at reversing the risk that it could mean for the patient's life, and on the other hand, on the resolution of the underlying pathology, which is the behavioral disorder, in order to avoid the recurrence of the condition.

We present the case of a 29-year-old patient with borderline personality disorder referred from her psychiatric center due to ingestion of several foreign bodies.

Keywords:

Foreign bodies, Emergency surgery, Psychiatric patient, Endoscopic, Gastrostomy.

Introduction

Foreign Body Ingestion (FBI) is rare in adults as compared with children [1]. Foreign body ingestion is accidental in 95 percent of cases and is usually related to food (fish, chicken bones, toothpicks) [2]. Foreign body ingestion in adults occur more frequently in older adults, in individuals with underlying psychiatric diseases or alcohol intoxication, in prison inmates, and for the purpose of drug trafficking [3].

Most (80 to 90%) ingested foreign bodies pass without the need of intervention [4]. Endoscopic intervention is required in 10 to 20 percent of patients; the urgency for endoscopy depends on the underlying clinical scenario and the nature of impaction (food versus foreign body) [5]. In some cases, endoscopy can be avoided if a radiograph immediately prior to the procedure reveals that the foreign body has passed [6]. Surgical intervention is required in less than 1 percent [7].

We present the case of a 29-year-old patient with borderline personality disorder who came to the emergency room of our hospital referred from her psychiatric center due to ingestion of several foreign bodies (domino pieces). After radiological verification and rejecting endoscopic treatment by the on-call endoscopist, urgent surgical intervention was decided to resolve the problem.

Case Report

We present the case of a 29-year-old patient with borderline personality disorder [1] who came to the emergency room of

our hospital referred from her psychiatric center due to a new episode of ingesting foreign bodies, this time domino pieces [2]. The patient is an old acquaintance of the hospitals in the area since she has been operated on, despite her youth, on six occasions in different hospitals, in all cases laparotomy was performed to resolve the condition (extraction of various foreign bodies of different kinds; chains, clips, batteries, plastic objects) [3], beginning his surgical journey in 2018. Apart from

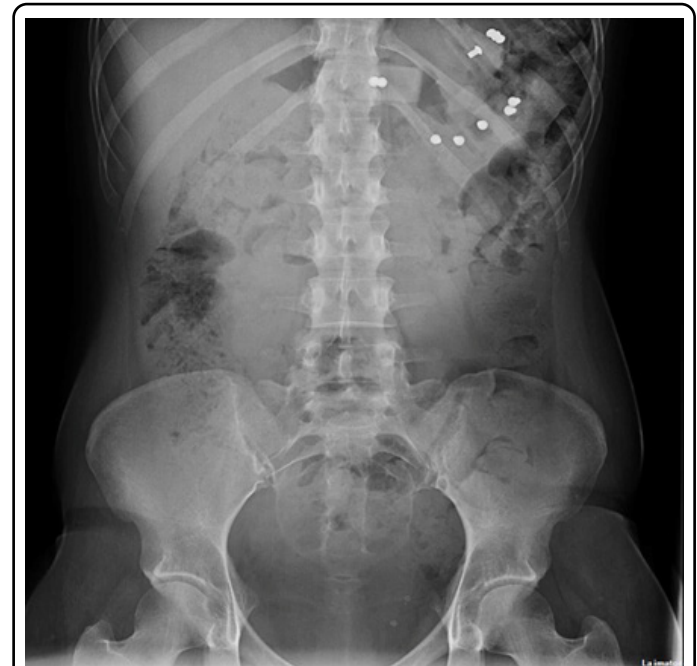

Figure 1: Abdominal X-ray where various foreign bodies are observed.

the six previous occasions in which she has required surgery, five successful endoscopic extractions have also been performed during this period [4].

Upon her arrival to the emergency room, she reported pain in the epigastrium without nausea or vomiting. On examination, she had a soft abdomen, painful to palpation in the epigastrium with midline eventration secondary to previous laparotomies. The chest and abdomen radiography (Figure 1,2) rules out pneumoperitoneum and confirms the presence of foreign bodies in the gastric chamber. Contacted the on-call endoscopist who, due to the number and size of the files, rejected endoscopic extraction.

Once identified and referenced, the gastrotomy was performed (Figure 4) with extraction of six dominoes (Figure 5,6). Closed the gastrotomy with continuous 2/0 absorbable monofilament suture, leaving Jackson Pratt drainage in the surgical bed.

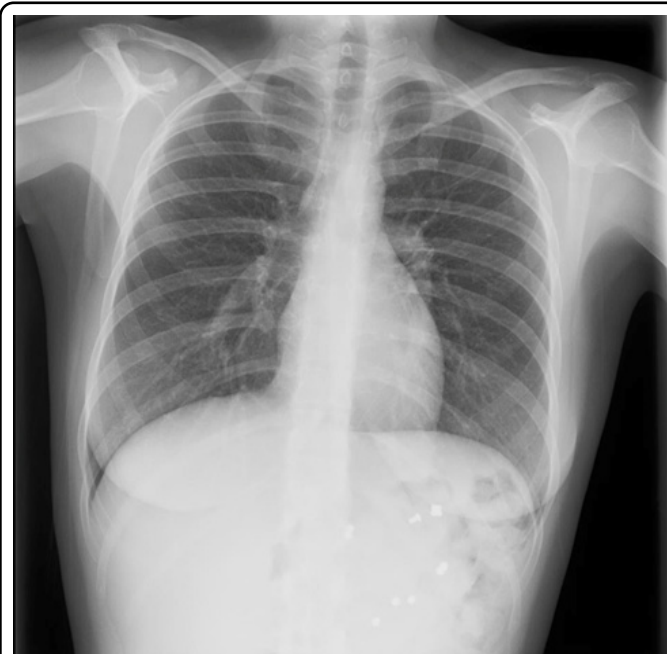

Figure 2: Chest x-ray that rules out pneumoperitoneum and also observed foreign bodies in the gastric chamber.

In this situation, a surgical revision is agreed upon. A new iterative midline laparotomy was performed, revealing an extensive subcutaneous hematoma that was drained to subsequently release the firm adhesions from the previous surgeries until the gastric chamber was identified (Figure 3).

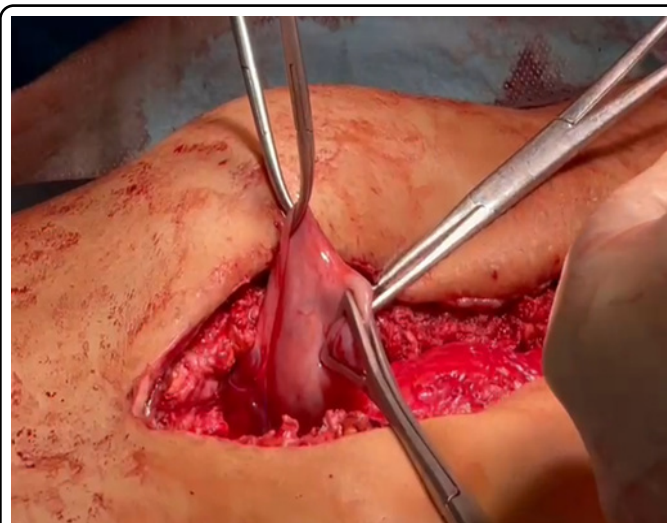


Figure 3: Identification of the gastric chamber.

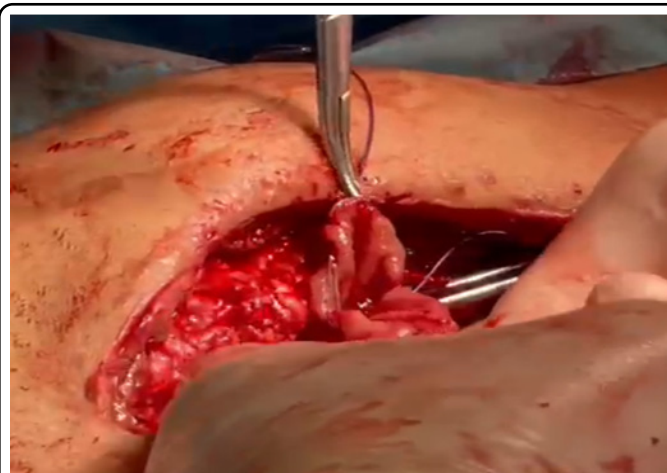


Figure 4: Gastrotomy performed.

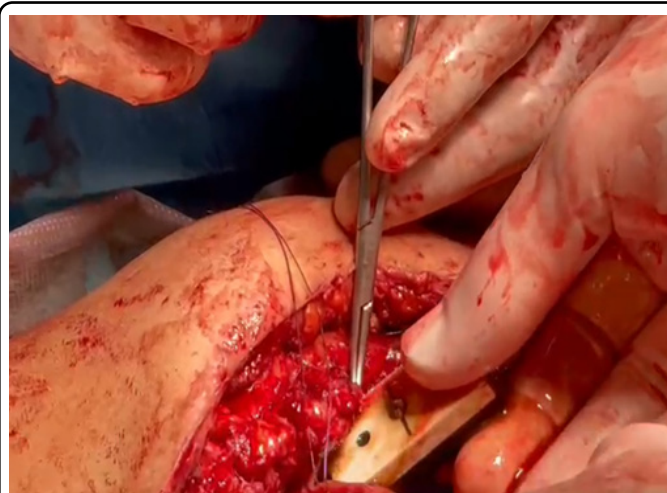


Figure 5: Removal of the foreign body.




Figure 6: Total material extracted.

The patient presented a good clinical evolution, maintaining suicidal ideas and with a high risk of escape, so contacted her psychiatric center where she was referred on the third postoperative day.

Discussion

Accidental ingestion of a foreign body is a common occurrence in the general population. 90% of cases resolve without incident spontaneously once they reach the stomach. Ingestion of a foreign body is carried out accidentally and involuntarily, and is more common in children and adolescents. It is also associated with patients with intellectual disabilities.

We have a special group of patients in whom intake occurs voluntarily and for different purposes. They are patients with affective, psychotic, personality disorders and/or intellectual disabilities, in which the purpose of ingesting foreign bodies is self-harming, self-lytic or seeks to mobilize their environment.

It has been described that 85% of patients who repeatedly ingest foreign bodies have an associated psychiatric disorder as their main diagnosis, and that 84% of deliberate ingestions occur in patients with a history of this behavior [5].

Symptoms will depend on the anatomical characteristics of the patient, and the places where the foreign body can become obstructed: esophagus, stomach, duodenum, small and large intestine. The reason for consultation in this type of patient, like our case, is generally given by the patient's own story, who tells us what he or she has ingested. Imaging tests such as simple chest and abdominal x-rays should be performed, and sometimes also abdominal CT depending on the nature of the foreign body or the suspected complication [6].

These are patients who will be treated in the emergency room by different professionals. The complications described are multiple, such as bronchoaspiration at the time of ingestion, pneumomediastinum and mediastinitis in the context of an esophageal perforation, digestive bleeding, perforation and fistula - especially in cases of sharp objects, intestinal obstruction, migration to neighboring organs, sepsis, multiple organ failure and death [7].

Until recently, the medical and psychiatric literature did not direct much attention to the prevention and behavioral therapy of behaviors associated with repeated foreign body ingestion [8]. In this regard, today the importance of prevention is beginning to be emphasized, often complicated by the characteristics of the patient and the limitation of resources. Obviously, efforts must be made to maintain a safe environment, in which objects that are easy to swallow are avoided within the reach of these patients [5].

They are restless patients, with difficulties staying confined to their room and therefore require constant and sustained supervision. Medical personnel must act without anger, with patience and serenity, without challenging the patient.

Psychiatric consultation is mandatory in this type of patient, to address their baseline pathology and in case of hospitalization, follow-up is necessary to prevent recurrences [6]. The behavioral approach by therapists can contribute and help reduce impulsive acts, attempts at self-harm, improve the capacity for self-control and develop more adaptive skills in the face of frustration or setbacks. The development of specific and effective institutional psychiatric protocols related to the repeated ingestion of foreign bodies is scarce due to the great complexity of the cases and the great diversity of the causes that trigger the patient to adopt this behavior of repeated and deliberate ingestion.

Strategic management is necessary at the institution level, with multidisciplinary care plans, with guidelines for active links between the different teams and services to avoid tensions and thus ensure good patient care.

Conflicts of Interest

Author declares there is no conflicts of interest.

Funding

No source of funding.

References

1. Ribas Y, Ruiz-Luna D, Garrido M, et al. Ingested foreign bodies: do we need a specific approach when treating inmates?. *Am Surg.* 2014;80(2):131-137.
2. Wu WT, Chiu CT, Kuo CJ, et al. Endoscopic management of suspected esophageal foreign body in adults. *Dis Esophagus.* 2011;24(3):131-137.
3. Liu Q, Liu F, Xie H, et al. Emergency Removal of Ingested Foreign Bodies in 586 Adults at a Single Hospital in China According to the European Society of Gastrointestinal Endoscopy (ESGE) Recommendations: A 10-Year Retrospective Study. *Med Sci Monit.* 2022;28:e936463.
4. Birk M, Bauerfeind P, Deprez PH, et al. Removal of foreign bodies in the upper gastrointestinal tract in adults: European Society of Gastrointestinal Endoscopy (ESGE) Clinical Guideline. *Endoscopy.* 2016;48(5):489-496.
5. Poynter BA, Hunter JJ, Coverdale JH, et al. Hard to swallow: a systematic review of deliberate foreign body ingestion. *Gen Hosp Psychiatry.* 2011;33(5):518-524.
6. Palese C, Al-Kawas FH. Repeat intentional foreign body ingestion: the importance of a multidisciplinary approach. *Gastroenterol Hepatol (N Y).* 2012;8(7):485-486.
7. Rodríguez Hermosa JI, Roig García J, Ruiz Feliú B, et al. Recurrent ingestion of foreign bodies and abdominal self-injury as a form of attempted suicide. *Gastroenterol Hepatol.* 2004;27(9):529-534.
8. Atluri D, Veluru C, Chopra A, Mullen KD. Recurrent Intentional Foreign Body Ingestion: An Endoscopist's Dilemma. *Gastroenterol Hepatol (N Y).* 2012;8(7):482-484.