

Case of a Sister Mary Joseph's Nodule in Pancreatic Adenocarcinoma: a Diagnostic challenge

Tarik Adioui* , Ahlame Benhamdane, Sanaa Berrag, Mouna Tamzaourte

Department of Gastroenterology, Military Hospital Mohammed V, Rabat, Morocco

Correspondence to: Tarik Adioui, Department of Gastroenterology, Military Hospital Mohammed V, Rabat, Morocco

Received date: November 23, 2022; **Accepted date:** December 15, 2022; **Published date:** December 22, 2022

Citation: Adioui T, Benhamdane A, Berrag S, et al. Case of a Sister Mary Joseph's Nodule in Pancreatic Adenocarcinoma: a Diagnostic challenge. *J Med Res Surg.* 2022; 3(6): 123-124. doi:10.52916/jmrs224094

Copyright: ©2022 Adioui T, et al. This is an open-access article distributed under the terms of the Creative Commons Attribution License, which permits unrestricted use, distribution and reproduction in any medium, provided the original author and source are credited.

ABSTRACT

Background: Sister Mary Joseph Nodule (SMJN) is a rare metastatic umbilical nodule with primary tumor genital or gastrointestinal sites. Pancreas is rare primary location for umbilical metastases. Pancreatic adenocarcinoma associated with SMJN usually arise from the body and tail of the pancreas. We report a case of SMJ nodule's as a cutaneous manifestation of metastatic pancreatic head cancer.

Case Report: A 59-year-old man, presented with epigastric, back pain and weight loss. On examination, an umbilical nodule was noted. Investigations confirmed a nodule of sister Mary Joseph as a pancreatic head cancer metastasis.

Discussion and Conclusion: SMJN nodule remains as a rare tumor with metastatic origin of cancer most commonly digestive. Due the poor prognosis, early detection and systematic biopsy of any nodule or umbilical mass is indispensable.

Keywords:

Sister Mary Joseph's Nodule (SMJN), Pancreatic cancer, Metastasis, Pancreas, Prognosis

Introduction

Sister Mary Joseph Nodule (SMJN) is a rare metastatic umbilical nodule with primary tumor genital or gastrointestinal sites [1,2]. Pancreas is rare primary location for umbilical metastases. Pancreatic adenocarcinoma associated with SMJN usually arise from the body and tail of the pancreas.

We report a case of SMJ nodule's as a cutaneous manifestation of metastatic pancreatic head cancer.

Case Report

A 59-year-old Congolese man with a medical history of recent

diabetes under metformin, presented with two months of epigastric, back pain and weight loss.

On physical exam, he was sub icteric and a painful ulcerated nodule measuring 1.5 cm was noted in the umbilicus (Figure 1). There was no abdominal mass or peripheral lymphadenopathy.

Hemogram showed an inflammatory anemia and C-Reactive Protein (CRP) was elevated.

Liver functions tests were abnormally elevated and tumor markers demonstrated a normal Carbohydrate Antigen (CA) 19-9 and Carcinoembryonic Antigen (CEA).

Abdominal Computed Tomography (CT) showed an umbilical mass consistent with Sister Mary Joseph's Nodule (SMJN) and a mass of the pancreatic head with dilated Common Bile Duct (CBD) and Main Pancreatic Duct (MPD). There was a multiple hepatic metastasis (Figure 2).

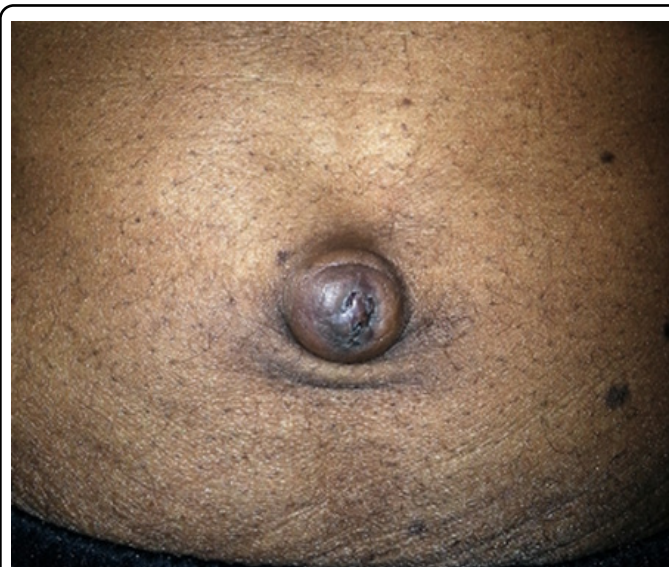

Figure 1: Abdominal examination showing an umbilical nodule.

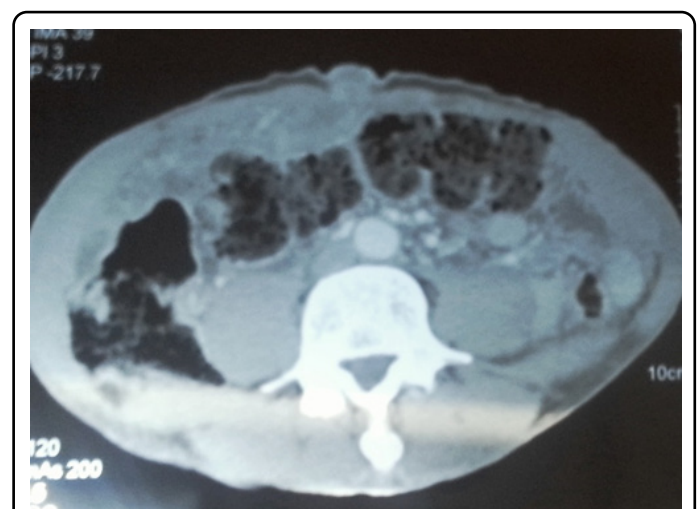


Figure 2: Computed Tomography (CT) revealing Sister Mary Joseph Nodule (SMJN) and a mass involving the head of the pancreas.

Biopsy of the umbilical mass revealed malignant cells and Immunohistochemistry (IHC) was consistent with pancreatic adenocarcinoma.

Patient was referred to oncology unit for palliation chemotherapy.

Discussion and Conclusion

Sister Mary Joseph Nodule (SMJN) refers to cutaneous metastases to the umbilicus from an abdominopelvic malignancy.

First described in 1854 by Baluff [3], this rare metastasis was recognized and better appreciated by Dr. William Mayo's assistant, Sister Mary Joseph, whose name has been used to describe it since 1949 [4-6].

Umbilical metastases are rare and only represent 2% of cutaneous cancer metastases [2]. The most common primary tumors in SMJN are stomach, ovarian and colon cancers [7]. Approximately 6% of umbilical metastases are pancreatic in origin [8].

Common sites of metastases in pancreatic cancer are lymph nodes, peritoneum, liver, lung, kidney; bone and brain [9].

Cutaneous metastases is rare with over 90% of pancreatic cancers associated with SMJN arise from the body and tail of the pancreas [10].

The mechanism of its spread to the umbilicus remains unclear. Several hypotheses were reported, the most frequent are intraperitoneal dissemination and implantation of pancreatic tumor cells on the umbilicus or direct invasion from peritoneal metastases. Alternative hypothesis for dissemination via the umbilicus includes invasion through vascular, lymphatic, or umbilical ligament [10,11].

The clinical appearance of NSMJ is variable; it is usually a firm, irregular and hard consistency nodule. Surface may be pigmented or ulcerated. The size varies from 0.5 to 2 cm, but certain nodules may reach 10 cm [12].

Diagnosis is based on fine needle aspiration cytology or biopsy. Adenocarcinoma represents 75% of SMJ nodules [13].

According to different studies, CA 19-9 AND CEA tend to be elevated in 70-80% of pancreatic cancer patients presenting cutaneous metastasis [14,15]. Contrary to the case study, this patient had a normal CA 19-9 and CEA level.

NSMJ have a poor prognosis with mean 11-month survival [13]. The prognosis is even worse in the diagnosis of pancreatic cancer with mean survival less than 3 months.

Treatment is commonly palliative and requires chemotherapy, radiotherapy or both.

In rare cases, aggressive surgery and adjuvant therapy may improve survival in patients with SMJN as a solitary metastasis [1,11].

In conclusion, the SMJN nodule remains as a rare tumor with metastatic origin of cancer most commonly digestive. Due the poor prognosis, early detection and systematic biopsy of any nodule or umbilical mass is indispensable.

Conflict of Interest

We have no known conflict of interest to disclose.

Consent to Publish

The patient has consented to the submission of the case report to the journal.

Funding

No.

References

1. Chalya PL, Mabula JB, Rambau PF, et al. Sister Mary Joseph's nodule at a University teaching hospital in northwestern Tanzania: A retrospective review of 34 cases. *World J Surg Oncol.* 2013;11: 151.
2. Gabriele R, Conte M, Egidi F, et al. Umbilical metastases: Current viewpoint. *World J Surg Oncol.* 2005;3: 13.
3. Husein-ElAhmed H, Aneiros-Fernandez J, Arias-Santiago S, et al. Morphology: Sister Mary Joseph's nodule as a metastasis of ovarian adenocarcinoma. *Int J Dermatol.* 2010;49: 1045–1046.
4. Key JD, Shephard DAE, Waiters W. Sister Mary Joseph's nodule and its relationship to diagnosis of carcinoma of the umbilicus. *Minn Med.* 1976;59: 561–566.
5. Powell FC, Cooper AJ, Massa MC, et al. Sister Mary Joseph's nodule: a clinical and histologic study. *J Am Acad Dermatol.* 1984;10(4): 610-615
6. Albano EA, Kanter J. Sister Mary Joseph's Nodule. *N Engl J Med.* 2005;352: 1913.
7. Poparic S, Prohic A, Kuskunovic-Vlahovljak S, et al. Sister Mary Joseph Nodule in an Ovary Adenocarcinoma. *Med Arch.* 2017;71: 154-157.
8. Shetty MR. Metastatic tumors of the umbilicus: A review 1830-1989. *J Surg Oncol.* 1990;45(3): 212–215.
9. Kaoutzanis C, Chang MC, Abdul Khalek FJ, et al. Non-umbilical cutaneous metastasis of a pancreatic adenocarcinoma. *BMJ Case Rep.* 2013;2013: bcr2012007931.
10. Yendluri V, Centeno B, Springett GM. Pancreatic cancer presenting as a Sister Mary Joseph's nodule: case report and update of the literature. *Pancreas.* 2007;34: 161-164.
11. Bolanaki H, Courcoutsakis N, Kouklakis G, et al. Sister Mary Joseph's nodule as the first sign of pancreatic carcinoma. *J Gastrointest Cancer.* 2012;43(Suppl 1): S254–S257.
12. Bailey H. Demonstrations of Physical Signs in Clinical Surgery. 11th ed. Baltimore, MD: Williams & Wilkins; 1949.
13. Dubreuil A, Domp Martin A, Barjot P, et al. Umbilical metastasis or Sister Mary Joseph's nodule. *Int J Dermatol.* 1998;37: 7–13.
14. Zhou HY, Wang XB, Gao F, et al. Cutaneous metastasis from pancreatic cancer: a case report and systematic review of the literature. *Oncol Lett.* 2014;8: 2654-2660.
15. Gui JC, Yan WL, Liu XD. CA19-9 and CA242 as tumor markers for the diagnosis of pancreatic cancer: a meta-analysis. *Clin Exp Med.* 2014;14: 225-233.